

Diagnosis of viral haemorrhagic septicaemia (VHS) in Iranian rainbow trout aquaculture by pathology and molecular techniques

A. Haghghi Khiabani^{1*}, M. Bandehpour²,
Z. Sharifnia² and B. Kazemi^{2, 3}

¹ Department of Pathology, Veterinary Sciences School, Islamic Azad University of Iran, Science and Research Campus, Tehran, Iran; ² Cellular and Molecular Biology Research Center, Shahid Beheshti University, M.C., Tehran, Iran; ³ Parasitology Department, Shahid Beheshti University, M.C., Tehran, Iran.

Abstract

To determine the disease status of Iranian rainbow trout aquaculture to viral haemorrhagic septicemia (VHS), research samples were collected from farmed rainbow trout populations that had symptoms of VHS disease. Fish were sampled between October 2004 and October 2006, from 100 rainbow trout sites in 10 provinces in Iran. Samples for diagnostic screening were aseptically collected from liver, kidney, spleen, bronchia, heart, intestine, and pancreas of rainbow trout with symptoms of VHS disease and all were screened by both molecular and pathological techniques. The first confirmed VHS disease outbreaks occurred in Iranian aquaculture in November 2005 at Rodsar of Gilan province in the north of the country. In this study of 100 rainbow trout fish farms, 15 positive sites were identified by pathology and 10 farms screened VHSV positive by nested-PCR. The results of this study reveal a potential high frequency of VHS virus in some centers of rainbow trout aquaculture in Iran and therefore the control and diagnosis of VHS disease is vitally important to the development of the Iranian rainbow trout aquaculture industry. This is the first study of VHS infection in rainbow trout aquaculture sites in Iran and highlights the need for routine diagnostic screening of aquaculture facilities to control the spread of VHS disease.

Introduction

Viral haemorrhagic septicaemia (VHS) is one of the most economically important viral disease problems in European salmonid aquaculture (Jorgensen, 1974). It has been widely reported that VHS disease can cause mass mortality in farmed rainbow trout (*Oncorhynchus mykiss*) of all ages. Recently, this disease was found in rainbow trout cultured in the Pacific Ocean and also in farms rearing marine species. Several cases of VHS disease have been reported in rainbow trout

breeding farms in Iran. Water temperature also plays an important role in the course of a VHS outbreak (Ahne & Thomsen, 1985), with the disease a more serious problem at water temperatures below 15-16°C (McAllister, 1979). Disease outbreaks usually occur between water temperatures of 4-14°C. The first VHS disease outbreaks occurred in Iranian aquaculture in November 2005 at Rodsar of Gilan province in the north of Iran with water temperatures measured at 10°C (unpublished data).

* Corresponding author's E-mail: dolmalid@yahoo.com

The VHS rhabdovirion, genus *Novirhabdovirus*, is an enveloped, bullet-shaped particle about 180 nm long and 60 nm in diameter. The intact virion is composed of five structural proteins and contains one segment of single stranded RNA (de Kinkelin & Scherrer, 1970; McAllister, 1979; de Kinkelin, 1983).

A variety of clinical signs and histopathological changes may be apparent in fish infected with VHS virus. Some fish show frank clinical manifestations of disease, whereas others appear healthy. Historically, clinical and pathologic signs of VHS have been catalogued into acute, chronic, and latent forms. Acute signs are typically accompanied by a rapid onset of heavy mortality, whereas the later or chronic stage is associated with lower mortalities, which occur over a protracted time period. It has also been reported that apparent virus carriers can demonstrate no clinical signs of VHS (Roberts, 2001). Disease signs of VHS include; fish that appear lethargic, dark in colour, exophthalmic, and anaemic. Haemorrhages are often evident in the eyes, skin, gills and at the bases of the fins. Internally, profuse haemorrhaging can be found in periocular tissues, skeletal muscle, and viscera, while congestion of the liver tissue and necrosis of the haematopoietic tissues can also be found (Bruno & Poppe, 1996).

Horizontal transmission of VHSV through contact with infected stocks or VHSV contaminated water supplies has been associated with several VHS outbreaks in European salmonid aquaculture. Other potential transmission routes include; virus-contaminated nets, boots, egg crates or other equipment. Feeding cultured fish with wet

fish food prepared from contaminated fish stocks can also transmit the virus. Such practices are considered high risk and should not be encouraged (Roberts & Shepherd, 1974). At present there is no evidence to suggest that VHSV can be vertically transmitted from parent to progeny.

There is no cure for VHS. Therefore, the best methods for the prevention of disease are based on prohibiting the use of the wet fish foods, minimising fish farm escapes, and ensuring that appropriate biosecurity practices are applied on all aquaculture facilities (Haghighi et al., 2007). In the case of a VHS outbreak on a farm, the site should be fallowed immediately and all holding ponds/tanks should be dried and disinfected. Disinfection should be performed at least three months before restocking of the aquaculture facility (Ahne & Thomsen, 1985).

The Office International des Epizooties (OIE), Manual of Diagnostic Tests for Aquatic Animals recommend that the following methods are used for VHS diagnosis:

1. Clinical signs of VHS disease.
2. Clinical methods (grosspathology – microscopicpathology - electron microscopy /cytopathology).
3. Agent detection and identification methods include; microscopic examination of histological sections, isolation of VHSV in cell culture then identification by one of the following confirmatory tests:- neutralisation assay, indirect fluorescent antibody test (IFAT), enzyme-linked antibody test (ELISA) and reverse-transcription polymerase chain reaction (OIE 2006).

Province (state)	Sample size Fish farms	Positive			
		Pathology		PCR	
		Total Positive cases	Percent Positive cases	Total Positive cases	Percent Positive cases
Mazandaran	25	2	8%	1	4%
Gilan	9	2	22.2%	1	11.1%
Ardebil	6	3	50%	1	16.6%
Lorestan	8	-	0	-	0
Markazi	4	2	50%	2	50%
North Khorasan	6	2	33.3%	2	33.3%
Kordestan	10	3	30%	3	30%
Kohkiloeh	12	1	8.3%	-	0
West Azarbayjan	8	-	0	-	0
Esfahan	12	-	0	-	0
Total	100	15	15%	10	10%

Table 1. Sampling of Iranian rainbow trout fish farms for VHS virus by PCR or pathological methods.

This manuscript describes the first detection of VHSV from farmed rainbow trout in Iran by molecular and pathological identification methods (Table 1).

Materials and methods

Sampling

All research samples were collected from farmed rainbow trout populations that had symptoms of VHS disease. Sixty fish were sampled from each farm, producing a 95% confidence that the disease would be detected at a 5% prevalence level, between October 2004 and October 2006. In total 100 rainbow trout farms in 10 provinces in Iran were sampled. Most of the fish sampled were rainbow trout fry, weighing between 3-5 grams, however from some sites in the Gilan, Mazandaran and Markazi (Arak) provinces rainbow trout broodfish were tested for VHSV. Disease outbreaks usually occurred

between the months of November and March, at lower water temperatures between 4-14°C. Tissue samples for both the pathological and molecular methods were aseptically dissected from anterior kidney, liver, spleen, heart, bronchi, intestine, pancreas, and muscle. Samples for histopathological examination were stored in saline formalin 10% (Merck, Iran) and PCR samples were stored in ethanol 20% and transmitted to the Biotechnology (molecular) laboratory. All tissues were processed within 24h of sampling.

RNA extraction: Viral RNA extraction was done by RNX^{plus} buffer following the manufacturers protocol (CinnaGen, Iran). Briefly, about 1 cubic mm of fish tissue was transferred to 1.5 ml micro tube, then 200 µl RNX plus buffer was added. The mixture was incubated for 5 min at room temperature, and then 50 ml of chloroform was added and

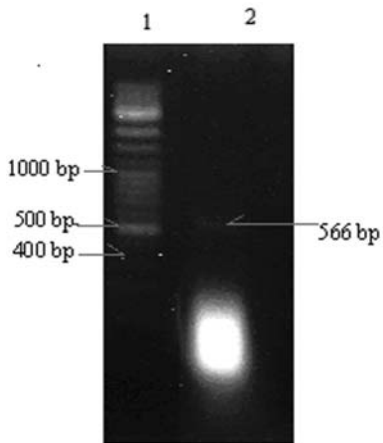


Figure 1. Agarose gel electrophoresis. Lane 1: 100 bp ladder DNA marker
Lane 2: 566 bp PCR product related to VHS virus glycoprotein gene.

centrifuged at 12000 rpm for 15 min at 4°C. Total tissue RNA (including viral RNA) was precipitated by ethanol, and then dissolved in 10 ml of diethyl pyrocarbonate treated water (Kazemi et al., 2004).

Reverse transcription reaction: Reverse transcription (RT) was performed as previously described (Pfeffer, 1988). Briefly, template RNA (1 ml) was incubated in a 20 ml reaction mixture containing: 40 pico mol of specific antisense external primer (VHS R 5'- TTT TGG AGT CAG TTT CCT CGC G - 3'), 100 unit of reverse transcriptase enzyme (RT) (Fermentas, Lithuania), 20 unit RNAsin (Fermentas, Lithuania), 1x RT buffer, 0.2 mM dNTP, for 1 h at 42°C.

PCR reaction: A nested-PCR was used to amplify a fragment of the viral glycoprotein gene. The first PCR reaction mixture contained 10µl of synthesized cDNA, 1.5 mM MgCl₂, 0.1 mM dNTP, 1X PCR buffer, 40 pico mol each forward and reverse primers and

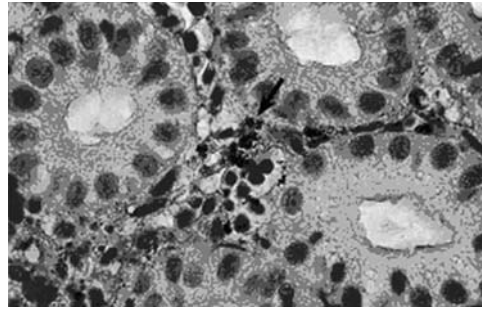


Figure 2. The histopathological section of kidney, staining with immunoperoxidase assay technique indicates the localized virus in kidney haematopoietic tissue (arrow).



Figure 3. Dissection of infected tissue with the typical signs as haemorrhage in swim bladder and visceral adipose caused by VHS.

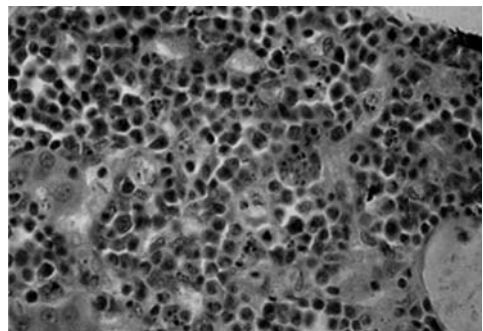


Figure 4. The histopathological section of kidney, severe cellular necrosis with disintegrated nuclei. (H&E staining).

1.25 unit of Taq DNA polymerase (CinnaGen, Iran). Primers for nested PCR were designed based on virus glycoprotein gene, Accession number Z93412 (Nest I primers: VHS F 5'-GTC CCA ACT CAG ATC ATC CAT C - 3' and VHS R 5'- TTT TGG AGT CAG TTT CCT CGC G - 3', amplified 617 bp of viral glycoprotein gene). The PCR was performed by 30 cycles of: denaturation at 94°C for 30 seconds, annealing at 58°C for 30 seconds and extension at 72°C for 40 seconds. 1 micro liter of PCR product was used as template DNA for the second PCR. The second PCR reaction was also performed within 30 cycles (Nest II primers: VHS2 F 5' - GCT ATC AGT CAC CAG CGT CTC - 3' and VHS2 R 5' - GGT CCT GTA ACC TGG ATC AGG - 3', amplified 566 bp of viral glycoprotein gene). Neither of the primer sets have been referenced previously.

Detection of PCR product: Electrophoresis of the PCR product was performed on a 2% agarose gel, stained by ethidium bromide and DNA banding was observed by UV light under UVTransilluminator.

Tissue preparation for histological methods: A standard tissue preparation method was applied, whereby all tissues from live or moribund fish were fixed in 10 % formalin for 24 hours. Samples were then embedded in a paraffin block and sectioned with digital microtome at 5-7 micrometer thickness. Slides were stained by haematoxilin and eosin, then treated with mounting media (Roberts, 2001). A small number of samples were confirmed VHSV positive by immunoperoxidase assay as previously described (Haghighi et al., 2007).

Results

Samples were screened by molecular and pathological assays. The results of this study are summarized in table 1. Out of 100 fish farms, 15 sites tested VHSV positive by pathology and 10 sites tested VHSV positive (positive cases) by nested-PCR.

Discussion

The results of this study indicate that VHS infection can be found in rainbow trout hatcheries and broodstock sites in Iran. To study the pathogenicity and to obtain isolates of VHS virus the establishment of a laboratory with virus culture equipment is necessary (de Kinkelin, 1983). The severity of VHS disease is dependant on the virulence of the virus strain, the immunological resistance of individual fish, stress factors and environmental conditions related to season, temperature, and pH changes (Ahne & Thomsen, 1985). An increased awareness of on-site hygiene and biosecurity rules, screening of broodstock populations for specific pathogens and isolation and quarantining of infected fish or fish with abnormal behaviour has played a major role in limiting the spread of VHS in Iran. Often, it is difficult to detect asymptomatic carriers of VHSV and this potentially could lead to a spread of infection. Therefore the innovation of sensitive and specific techniques for the detection of VHSV, such as PCR is necessary (OIE, 2006 & Naca, 1991). Other techniques such as the ELISA method (Meier & Jorgensen, 1975) immunohistochemistry (Haghighi et al., 2007), and IFAT (OIE, 2006) are also useful diagnostic tools for screening fish populations for VHSV.

VHS is found in the farms of rainbow trout breeding and propagation in Iran and both PCR and pathological techniques are useful for the diagnosis of disease and these methods have almost perfect agreement.

Acknowledgement

This research was supported by Iranian Veterinary organization and was done in Cellular and Molecular Biology Research Center, Shahid Beheshti University, M.C., authors will pass best regards and thanks to them.

References

Ahne W & Thomsen I (1985). Occurrence of viral hemorrhagic septicemia virus in wild whitefish *Coregonus* sp. *Zentralbl. Veterinaermed. Reihe B* **32**, 7375.

Bruno DW & Poppe TT (1996). A colour atlas of salmonid diseases. Academic Press, London. ISBN 0-12-137810-1.

de Kinkelin P & Scherrer R (1970). Le Virus d'Egtved I. Stabilité, développement et structure du virus de la souche danoise F1. *Annales de Recherches Veterinaires (Paris)* **1**, 1730 (in French).

de Kinkelin P (1983). Viral haemorrhagic septicaemia. In **"Antigens of fish pathogens"** (D.P. Anderson, M. Dorson and Ph. Dubourget, Eds.), pp. 5162. Fondation Marcel Merieux, Lyon, France.

Haghighi A, Soltani M, Kazemi B, Sohrabi I & Sharifpour I (2007). Use of Immunohistochemical and PCR Methods in Diagnosis of Infection Haematopoietic Necrosis Disease in some Rainbow Trout Hatcheries in Iran. *Pakistan Journal of Biological Sciences* **10**(2), 230- 234.

Jorgensen PEV (1974). A study of viral diseases in Danish rainbow trout, their diagnosis and control. Commissioned by A/S Carl Fr. Mortensen, Bulowsvej 5 C, 1870 Kobenhavn V, Denmark, pp. 101.

Kazemi B, Bandehpour M, Yahyazadeh H, Roozbehi M, Seyed N, Ghotasloo A & Taherpour A (2004). Comparative study on HCV detection in Iranian patients by RT-PCR and ELISA techniques during 2001-2003. *Journal of Medical Science* **4**(2), 132- 135.

McAllister PE (1979). Fish viruses and viral infections. In **"Comprehensive virology"** (H. Fraenkel-Conrat and R.R. Wagner, Eds.), vol. 14, p. 401-470. Plenum Publishing Corp., New York.

Naca (1991) Fish health management in Asia-Pacific Report on a Regional study and workshop on fish disease and fish health management ADB Agriculture Department Report series No. 1 June 1991 Bangkok, Thailand 627 pp. viral disease chapter, pp 340-355.

The Office International des Epizooties (OIE) (2006). Manual of Diagnostic Tests for Aquatic Animals. Fifth edition, Notifiable disease chapter 2.1.5. pp. 141-158.

Pfeffer U (1988). One – Tube RT – PCR with sequence – Specific Primers. In **"RNA isolation and characterization protocols"**, (R. Rapley and D.L. Manning, Eds.), pp. 143-151. Humana Press.

Roberts RJ (2001). Fish pathology. Bailliere Tindall, London. Virology pp. 238-243 and pp. 386-387.

Roberts RJ & Shepherd CJ (1974). Handbook of Trout and salmon Disease the white friars, pp 168. Ltd, London and Cambridge.